

## Histological aberrations accompanying chronic metal toxicity in the mussel *Perna indica*

Philip Mathew and N.R. Menon\*

Dept. of Zoology, Sacred Heart College, Thevara, Cochin -682 013, India

\* IMCOZ, School of Marine Sciences, Cochin University of Science and Technology, Fine Arts Avenue, Cochin -682 016, India

### Abstract

Evidences gathered from the observations made on the structure of gills and digestive tubules of *Perna indica* clearly indicate that prolonged exposure to low levels of mercury, copper and cadmium individually or in concert would damage the tissues extensively. Even low levels of heavy metals when encountered by the mussel resulted in extensive disintegration of these sensitive tissues. Presence of more than one metal concomitantly resulted in greater damage of the tissues. Chronic exposure studies employing polluted media would help in establishing histopathological criteria to assess pollutional effects for incorporation in monitoring strategies.

**Keywords:** Metal toxicity, histological aberrations, mussel, *Perna indica*

### Introduction

The effect of a toxic compound on an aquatic species could be direct, induced or indirect. Chronic direct effects and induced effects of toxicant exposures are of particular importance to those concerned with the aquatic environment. The organisms here are extremely vulnerable to toxic effects resulting from absorption or oral intake of contaminants from the immediate environment. Toxicological studies of aquatic organisms have not revealed many tissue pathologies useful in diagnosing effects of exposures to specific compounds. Histopathological studies on the tissues of fishes and shrimps exposed to different heavy metals produced non-specific microscopic lesions which include, epithelial hyperplasia with lamellar fusion, epithelial hypertrophy, telangiectasia, oedema with epithelial separation from basement membranes, general necrosis and/or epithelial desquamation (Gilderhaus, 1966; Gardner and Yevich, 1970; Eisler and Gardner, 1973; Bhatnagar and Shrivastava, 1975; Wobeser, 1975 a, b; Establier *et al.*, 1978 a, b and Manisseri and Menon, 1995). Auffret (1988) observed that *Mytilus edulis* exposed to high concentrations of diesel oil and copper mixture showed severe degenerative changes in the epithelium of the digestive gland. Further, these mussels exhibited disturbance of the ciliated epithelial cells, when compared to those from control and low concentration exposures. Similar lesions have been reported in mussels exposed to sub-lethal copper and cadmium (Sunila, 1986) and copper and mercury exposures (Krishnakumar *et al.*,

1990). Establier *et al.* (1978 b) observed that following exposure to CdCl<sub>2</sub>, the hepatopancreas (digestive diverticula) in some invertebrates showed atrophy, reduction in height of tubular epithelium, tubular dilation, necrosis and desquamation of tubular epithelium.

Lesions have been extremely non-specific and merely indicative of toxic insult. Most toxicant induced tissue pathology examined has been non-specific and this is not surprising as aquatic toxipathology is in its infancy. Marine bivalves are of particular interest because of their known capacity to accumulate trace metals and other toxicants. Among the marine invertebrates studied, molluscs stand apart as useful experimental animals to identify and delineate histopathological effects due to chronic exposure to heavy metals. The present paper deals with the histopathology of the gills and digestive tubules of *P. indica*, subjected to prolonged exposure to sub-lethal concentrations of mercury, copper and cadmium, individually and in combination.

### Materials and methods

Specimens of *P. indica* (size range: 20-25 mm) were dislodged from the rocky beaches of Shakthikulangara (76°34' 24" Long; 9°56' 9" Lat) in Quilon along the South West coast of India, transported to the laboratory, cleaned off the epibionts and maintained under laboratory conditions for 36hr prior to experimentation in aerated sea

water (room temperature:  $30 \pm 10^\circ\text{C}$ ; salinity:  $\sim 32\text{‰}$ ; pH: 8.2-8.4), with daily renewal of the medium. Maintenance of animals in the laboratory prior to experiments and during the course of experiments was done under optimum conditions. The seawater used for the experiments was collected from the Arabian Sea off Cochin. Before experiments, the sea water was filtered using a biofilter and aerated to full saturation.  $\text{CuSO}_4 \cdot 5\text{H}_2\text{O}$ ,  $\text{HgCl}_2$  and  $\text{CdCl}_2 \cdot \text{H}_2\text{O}$  were the source of copper, mercury and cadmium. Stock solutions of the toxicants were prepared in double glass-distilled water and added to the culture media to achieve the desired concentration. The addition of the toxicants did not produce any appreciable variation in the pH.

Ten animals each were pre-exposed to 10 ppb of mercury, 6 ppb of copper and 400 ppb of cadmium, individually and in combination, for 21 days along with control. Duplicates were maintained for both control and treatment groups with daily replenishment of the culture medium. The animals were fed regularly with the *Synechocystis salina*, for 2 hr before the medium was renewed. After 21 days of exposure, the animals were dissected and the soft tissues of the whole animal were carefully scooped out, fixed in Bouin's fixative, washed with several changes of 70% ethanol, dehydrated, cleared in methyl benzoate, infiltrated and embedded in paraffin wax (mp:  $60\text{--}62^\circ\text{C}$ ). Sections were cut at  $10 \mu\text{m}$  with a rotary microtome and stained with Papanicolaou stain and examined under Zeiss photomicroscope.

## Results

In control animals the gill filaments showed the normal structure of a bivalve ctenidium with the central core tissue of the filaments and well arranged epithelial cells, having lateral and frontal cilia (Fig. 1A). It is also noticed that the lateral cilia more or less overlap with the adjacent filaments. The epithelial cells are normal with laterally placed nuclei. The epithelial cells of the digestive gland tubules are arranged normally and there is no enlargement of primary lysosomes or the appearance of secondary lysosomes (Fig. 1B).

The structure of the gill filaments and digestive tubules exposed to 10 ppb of mercury for 21 days indicated that the lateral and frontal cilia have sloughed off and the lumen of the gill filaments had wandering blood cells (Fig. 1C). Further, spaces have developed between the gill lamina and the cells. The digestive tubule showed degeneration and the vacuolar nature of the cells probably indicates damages brought about by metal toxicity (Fig. 1D). Following exposure to 6 ppb of copper, the gill filaments were thoroughly damaged and the cells have

been destroyed with enlargement of the gill lumen (Fig. 1E). The changes that occurred in the digestive tubule in response to copper exposure mainly relates to total damage of cells. However, it is not clear whether secondary lysosomes have developed, although vacuolar regions are seen in the section (Fig. 1F). A conspicuous feature of the gills exposed to 400 ppb of cadmium was the bulging of the distal ends of the filaments (Fig. 1G). This evidently was the effect of enlargement of filamentar lumen, together with damage and disintegration of the median and proximal cells on the filaments. The distal cilia were found missing although lateral cilia were found clumped together. The damage that occurred to the digestive tubules was not very clear although certain cells in the tubule were reduced in size (Fig. 1H).

*P. indica* was exposed to a combination of mercury and copper for 21 days and the pathological effects on the gills and digestive tubules were assessed. It was noticed that the gill filaments have become distorted. No conspicuous cellular damage was noticed although distal cilia were damaged (Fig. 2A). Total degeneration of digestive tubules was indicated and the lumen contained dislodged cells. However, enlargement of cells was not evident (Fig. 2B). Exposure to a combination of mercury and cadmium produced conspicuous damage to the gill filaments (Fig. 2C). In the case of gastric tubules, the formation of secondary lysosomes in the form of large vacuoles and deposited in the lumen were the two dislodgement of cells, the same being conspicuous effects (Fig. 2D). Exposure to a combination of copper and cadmium resulted in enlargement of the gill filamentar tips and rupture of the lumen (Fig. 2E). While the general architecture of the digestive tubules remained unaltered, large vacuoles were found inside the cells of the tubules (Fig. 2F). Exposure to a triad combination of mercury, copper and cadmium resulted in the total damage of gill filaments and they would have become non-functional (Fig. 2G). The digestive tubule showed extensive disintegration of cells, resulting in a reduction in the number of functional cells. Extensive vacuolization of some of the tubular cells was also indicative of the toxic effects (Fig. H).

## Discussion

Toxicological investigations of organisms normally centre on assessment of physiological mal-functioning and morphological aberrations. It is understood that the physiological mal-functions are due to histological damage and functional aberrations of tissues. While physiology is mainly assessed by rate functions, histopathology looks into evidences based on actual damage. Controversy still exists regarding the site and the mode of entry of heavy metals into the tissues of marine mussels. Invest-

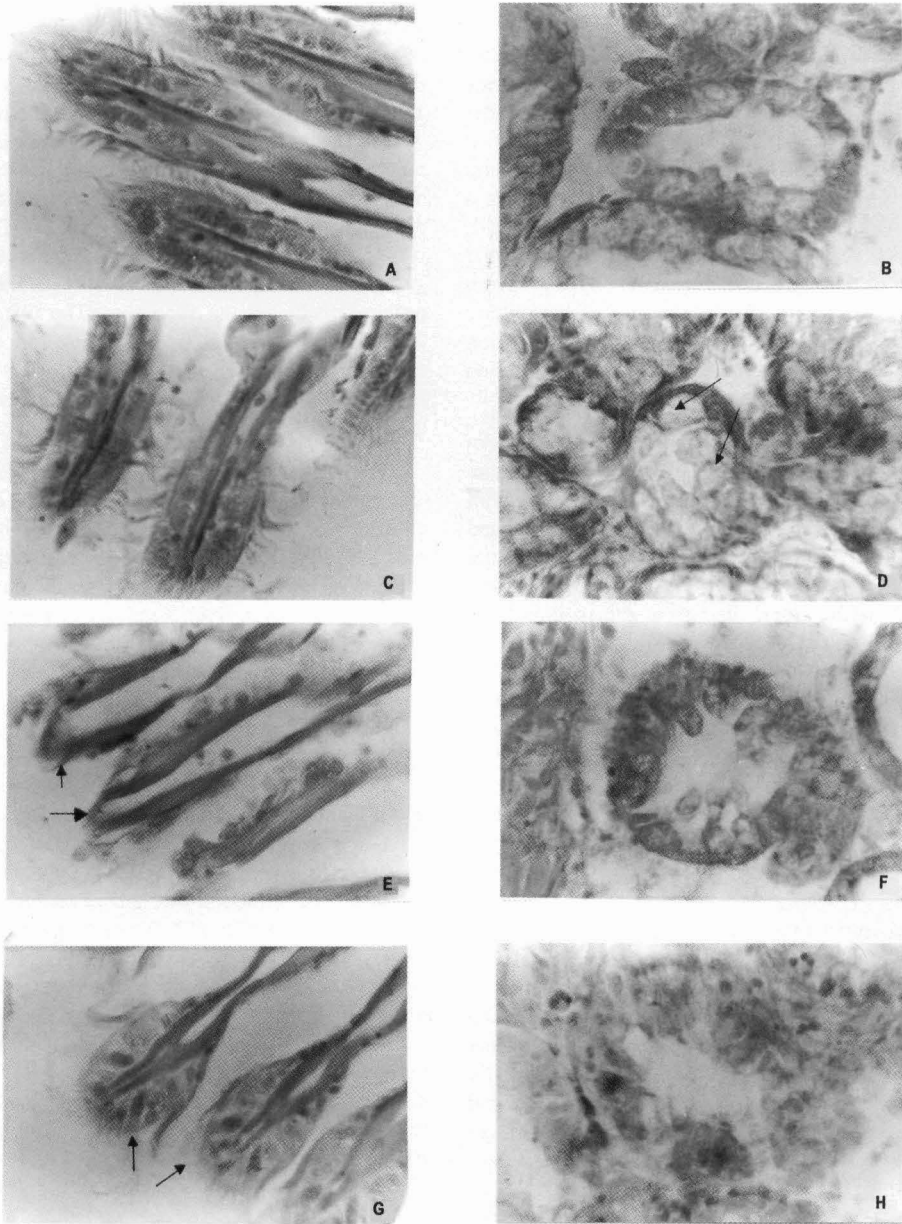


Fig.1. CS of gills (GI) and digestive tubules (Dt) of *Perna indica*. A) GI (Control) X 1000. B) Dt (Control) X1000. C) GI exposed to 10 ppb of Hg for 21 d X 1000. D) Dt exposed to 10 ppb of Hg for 21d X 1000. ↑ vacuolated epithelial cells. E) GI exposed to

6.0 ppb of Cu for 21 d X 1000. ↑ damaged gill filaments. F) Dt exposed to 6.0 ppb of Cu for 21d X 1000. G) GI exposed to 400 ppb of Cd for 21 d X 1000. ↑ enlarged epithelial cells. H) Dt exposed to 400 ppb of Cd for 21d X 1000.

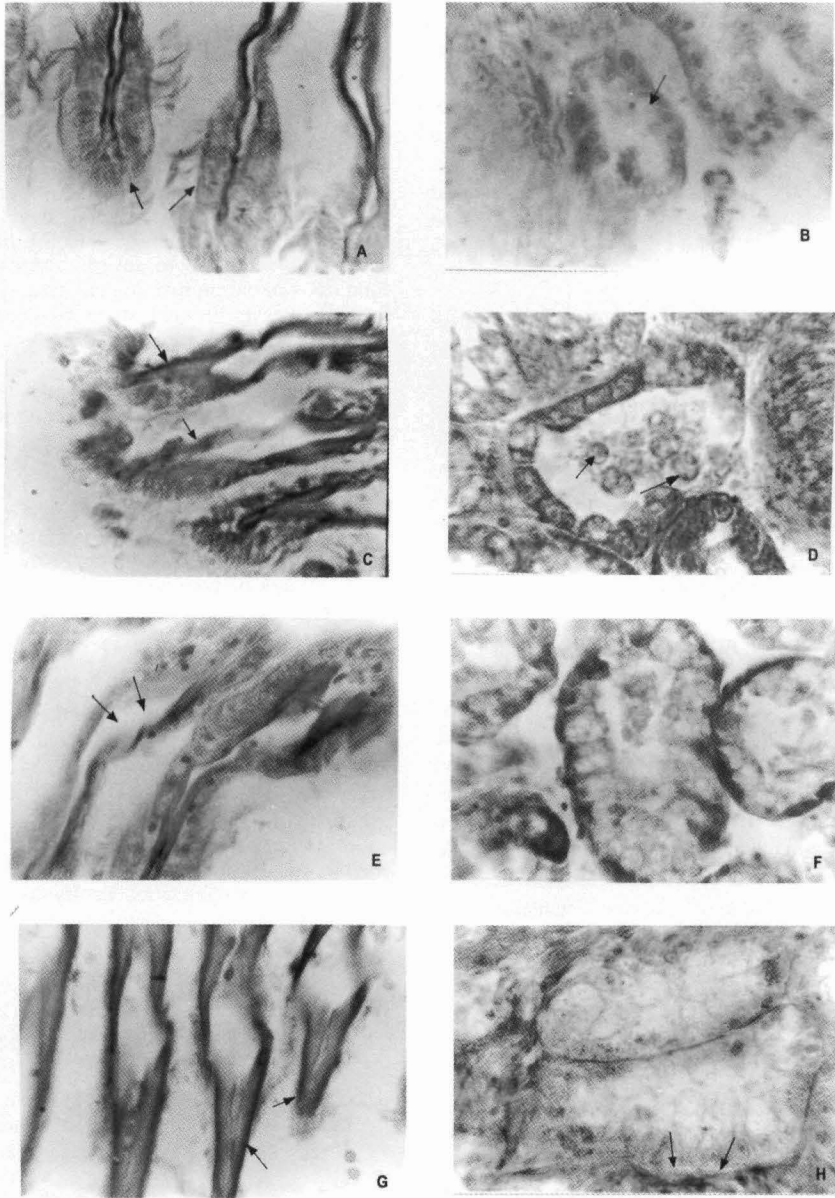


Fig.2. CS of gills (GI) and digestive tubules (Dt) of *Perna indica*. A) GI exposed to 10 ppb of Hg and 6.0 ppb of Cu for 21 d X 1000. ↑ damaged gill filaments. B) Dt exposed to 10 ppb of Hg and 6.0 ppb of Cu for 21 d X 1000. ↑ disintegrated digestive tubules. C) GI exposed to 10 ppb of Hg and 400 ppb of Cd for 21 d X 1000. ↑ denuded gill filaments. D) Dt exposed to 10 ppb of Hg and 400 ppb of Cd for 21 d X 1000.

↑ sloughing off of epithelial cells. E) GI exposed to 6.0 ppb of Cu and 400 ppb of Cd for 21 d X 1000. ↑ enlarged filamentar tips. F) Dt exposed to 6.0 ppb of Cu and 400 ppb of Cd for 21 d X 1000. G) GI exposed to 10 ppb of Hg, 6.0 ppb of Cu and 400 ppb of Cd for 21 d X 1000. ↑ denuded gill filaments. H) Dt exposed to 10 ppb of Hg, 6.0 ppb of Cu and 400 ppb of Cd for 21 d X 1000. ↑ dislodged epithelial layer.

tigations conducted employing dissolved and particulate fractions of copper have shown that copper in dissolved form is much more toxic than in particulate form. This has a direct reflection on the mode of entry. Copper would have entered in the dissolved form mainly through the respiratory surface while that in particulate form through the gut. Therefore, the damage of tissues, if it is a direct effect of heavy metal entry, should vary in extent and dimension, depending on the nature of availability of the toxicant (Menon and Widdows, personal communication).

The experimental animals were fed during the course of the experiments. Therefore, the heavy metals would have entered the animal's tissues through water as well as food. It is known that diatoms have the capacity to chelate heavy metal ions (Hawkins and Bayne, 1984). Therefore, to have a comparison on the extent of damage owing to the entry of heavy metals through respiratory or through digestive surfaces, the gills and the digestive tubules of the affected animals were examined.

Observation of the tissues has shown that there were pathological changes in the epithelium of the digestive tract as well as the gills. Brown coloured secondary and tertiary lysosomes are known to be conspicuous features in the digestive cells of the tubules (Auffret, 1988). The incidence of these lysosomes is known to be xenobiotic induced cellular pathology, disturbing the structure and function (Moore, 1982; 1985). Sloughing off of epithelial cells from the gill filaments seems to be a normal pathological indicator of heavy metal exposure. This should be the after effect of initial mal-functioning and death of cells leading to sloughing off. Severe degeneration of epithelial cells of the digestive gland has been recorded as an indicator of exposure to high concentrations of copper. The appearance of such cellular disturbances in the sections obtained during this investigation support the hypothesis that autolytic processes are a consequence of full lysosomal destabilization, put forward by Moore (1985). The presence of thoroughly damaged epithelial layer of the digestive tubules is an indication of necrosis leading to tubular degeneration. The vacuolation of cells of the digestive tubules may be due to the formation of membrane bound vesicles containing accumulated heavy metals as electron dense granules or perhaps be related to vesiculation of endoplasmic reticulum as a result of failure of ion pump (Manisseri and Menon, 1995). It may be assumed here that chronically induced injuries are responsible for such lesions. Changes in the morphology of gill filaments accompanied by severe degeneration of ciliated epithelial cells have been reported in the case of mussels exposed to sub-lethal thermal stress and to contamination by heavy metals (Gonzales and Yevich, 1976; Sunila,

1986). The fact that these pathological indications have occurred both in the case of natural and man made disturbances, clearly indicate that the observed damage of gills reported during the present investigation is a general phenomenon that could occur to mussels exposed to a stress and that it is not restricted to chronically induced toxication. Definition of histopathological evidences as indicators of chronic pollutional stress could be achieved only if the method is standardized by incorporating this as a component of ecosystemic evaluation studies of chronically polluted areas. On the other hand, examination of animals subjected to severe stress under laboratory conditions based on histological studies cannot fully reflect the effects brought about by contaminants alone. Auffret (1988) has been sceptical about dose-dependent histopathological evidences in mussels, although he did assume that histopathology could give useful information on sub-lethal effects of chemical contamination. Epithelial cell shrinkage and erosion of cells noticed in the present instance have been suggested as the effects of chemical contamination by Lowe (1988) in *Mytilus edulis*. According to him strict lack of agreement between biological evidence of pollution on tissue chemistry and histopathology may be due to lack of understanding of the more subtle effects of combined toxicity. The only evidence noticed was greater damage of tissues when more than one metal was responsible for the insult.

#### Acknowledgement

One of the authors (P.M.) is thankful to the University Grants Commission, New Delhi, for the award of Fellowship during the tenure of which the present work was carried out.

#### References

- Auffret, M. 1988. Histopathological changes related to chemical contamination in *Mytilus edulis* from field and experimental conditions. *Mar. Ecol. Prog. Ser.*, 46: 101-107.
- Bhatnagar, S.J. and R.S. Shrivastava. 1975. Histopathological changes due to copper in *Heteropneustes fossilis* (Abstract). *Indian Sci. Congr. Assoc. Proc.*, 62:173 pp.
- Eisler, R. and G.R. Gardner. 1973. Acute toxicology to an estuarine teleost of mixtures of cadmium, copper and zinc salts. *J. Fish. Biol.*, 5:131-142.
- Establier, R., M. Gutierrez and A. Arias. 1978 a. Accumulation and histopathological effects of inorganic and organic mercury in the lisa (*Mugil auratus* Risso). *Invest. Pesq.*, 42:65-80.
- and A. Rodriguez. 1978 b. Accumulation of cadmium in the muscle and hepatopancreas of the shrimp (*Penaeus kerathurus*) and histopathological alterations produced. *Invest. Pesq.*, 42:299-304.
- Gardner, G.R. and P.P. Yevich. 1970. Histological and haematological responses of an estuarine teleost to cadmium. *J. Fish. Res. Bd. Can.*, 27:2185-2196.

- Gilderhaus, P.A. 1966. Some effects of sub-lethal concentrations of sodium arsenite on bluegills and the aquatic environment. *Trans. Am. Fish. Soc.*, 95:289-296.
- Gonzales, J.G. and P.P. Yevich. 1976. Responses of an estuarine population of the blue mussel *Mytilus edulis* to heated water from a steam generating plant. *Mar. Biol.*, 34:177-189.
- Hawkins, A.J.S. and B.L. Bayne. 1984. Seasonal variation in the balance between physiological mechanisms of feeding and digestion in Bivalvia: Mollusca. *Mar. Biol.*, 82:233-240.
- Krishnakumar, P.K., P.K. Asokan and V.K. Pillai. 1990. Physiological and cellular responses to copper and mercury in the green mussel *P. viridis* (Linnaeus). *Aquat. Toxicol.*, 18 :163-174.
- Lowe, D.M. 1988. Alterations in cellular structure of *Mytilus edulis* resulting from exposure to environmental contaminants under field and experimental conditions. *Mar. Ecol. Prog. Ser.*, 46: 91-100.
- Manisseri, K. and N.R. Menon. 1995. Copper induced damage to the hepatopancreas of the penaeid shrimp *Metapenaeus dobsoni*-an ultra structure study. *Dis. Aquat. Org.*, 22: 51-57.
- Moore, M.N. 1982. Lysosomes and environmental stress. *ibid.* 13:42-43.
- 1985. Cellular responses to pollutants. *Mar. Pollut. Bull.*, 16: 134-139.
- Sunila, I. 1986. Chronic histopathological effects of short-term copper and cadmium exposure on the gills of the mussel, *Mytilus edulis*. *J. invert. Pathol.*, 47: 125-142.
- Wobeser, G. 1975 a. Acute toxicity of methyl mercury chloride and mercuric chloride for rainbow trout (*Salmo gairdneri*) fry and fingerlings. *J. Fish. Res. Bd. Can.*, 32: 2005-2013.
- 1975 b. Prolonged oral administration of methyl mercury chloride to rainbow trout (*Salmo gairdneri*) fingerlings. *ibid.*, 32: 2015-2023.

Accepted: 15 June 2005